Physiology. — *Annotations on the physiology and the anatomy of a dog, living 38 days, without both hemispheres of the cerebrum and without cerebellum.* By Dr. G. G. J. RADEMAKER and Dr. C. WINKLER.

(Communicated at the meeting of April 28, 1928).

Until now, different workers have not succeeded in keeping long enough alive a dog, after the removal of both hemispheres and cerebellum, to do physiological and anatomical researches on it.

Such researches may have a great interest for :

1⁰. a physiology of the higher parts of the central system, wanting to be freed from the psychological nomenclature in which it is, necessarily at present, bound ;

2⁰. an anatomy, wanting to know the systematic architecture of those higher parts, which till now, is only known very roughly.

Dr. RADEMAKER has tried to produce such animals for research, forced by considerations, from which he gives the following report.

Total or partial removal of the cerebellum in normal young animals has not answered in a sufficient way the question : what function may be practised by the cerebellum ?

It was his endeavour to solve this question, by removing the cerebellum in animals without hemispheres.

It could be expected, that the loss of all conditioned reflexes after extirpation of the hemispheres might simplify the symptoms of the removal of the cerebellum.

Firstly, the comparison of the behaviour of animals without hemispheres before and after the loss of the cerebellum should probably produce more distinct facts to enable us to understand the cerebellar function.

Secondly : the study of the compensation of the symptoms produced by cerebellar removal in normal animals, compared with those after such removal in animals without hemispheres, should open the possibility of determining the part, played by the hemispheres in compensating disorders caused by cerebellar removal.

For most workers believe, that the transient cerebellar disorders, which gradually pass to a certain extent, after cerebellar removal in normal animals, are compensated for by the function of the hemispheres, though nobody has made special experiments upon this question.

And lastly. Only by removal of the cerebellum after that of the hemispheres, can it be for certainty fixed, which function the brainstem may perform without being influenced by cerebrum and cerebellum.

The dog, now presented to you, is an animal, living 38 days without

hemispheres and without cerebellum. At the first operation, on December 9th 1926, 97 days before death, the left hemisphere has been taken away; 20 days afterwards, on December 29th 1926, 77 days before death, the right hemisphere was extirpated, and the 7th of February 1927, 38 days before death, the cerebellum was removed.

All operations were very well supported. Difficulties in the regulation of the warmth of the animal, of its feeding, of its uncleanliness were overcome by the well-trained nursery-knowledge and the devotion of Mrs. RADEMAKER. But a fortnight before death, an infectious distemper of dogs made its entrance into the kennels. Fever, purulent rhinitis and conjunctivitis, frequent respiration, coughing and sneezing occurred. The animal died at the 17th of March 1927. At the autopsia were found, purulent bronchitis and pneumonia and an empyema of the right frontal sinus.

In the short time in which research was possible, different interesting facts were noticed.

After the removal of the left hemisphere, the animal walked mostly in a circle to the left, counter-clockwise.

The preference for walking to the left, persisted after the removal of the right hemisphere, contrarely to what is ordinarily seen. This had been the only asymetrical disorder seen in the animal after the removal of both hemispheres.

It is difficult to prove, that this symptom was caused by the removal of the striatum at the left side and the nearly absolute sparing of the striatum at the right side, as the anatomy taught us (fig. 43—96 of the series).

After the extirpation of both hemispheres the animal had the ordinary symptoms, described by many investigators.

1°. the animal is blind, deaf and cannot smell, if one regards the extensive reactions, which the normal animal produces on optic, acustic and olfactive stimulations, as a measure for seeing, hearing and smelling.

2°. the animal walks practically as a normal dog walks, setting his paws on the earth in the proper position and making no errors in keeping his equilibrium (fig. 1).

3°. the animal has lost all the reactions of position of the legs, and all the reactions of correction made by the extremities, originated by the surface of its body (fig. 2).

4°. the supporting-tonus of the hind-legs has much diminished. They bend promptly at a slight pression upon the pelvis or when a sandbag of 2 kg is put on the back of the animal. But the tonus of support has not altered in the forelegs.

Now, as in this animal without hemispheres, the removal of the cerebellum was executed, the same disorders were seen as in a normal animal after the decerebrate section of SHERRINGTON. The animal had stiffened. Without trying to stand up, the animal placed on its back, retained this position with its neck stretched backward, with its stiffened back bent convexely, and with the four extremities totally stretched and

stiffened, resisting violently every passive flexion. The stretched tonus was the so-called plastic tonus ; it presented the clasp-knife phenomenon and did not disappear after passive flexion of the distal joints of the extremity. After a week, this rigidity could still be seen, in the second-third week it disappeared (fig. 3).

After varying the position of the head against the trunk and still more after varying the position of the head in space, the extension-rigidity could be seen diminishing or augmenting (tonic cervical- and labyrinthic-reflexes of MAGNUS and DE KLEYN).

However, at the end of the first week, the extension-tonus of the hind-legs still being augmented, only a very slight supporting-tonus could be shown in them. A pressure of 2 kg exerced on the sole was sufficient to bend them (fig. 4).

On the contrary a pression of 10 kg, exerced on the sole of the foreleg was supported, without bending, and if a sandbag of 5 kg was placed upon the shoulders, the forelegs did not bend (the dog's weight was 6.5 kg) (fig. 4).

In the course of the second to the fourth week after the cerebellar removal, the rigidity disappeared and the animal made attempts to right himself.

The labyrinth-righting-reflexes returned, the supporting-tonus of the hind-legs augmented, positive and negative reactions of support and different other reactions of the extremities were seen again.

If the animal was put on his hind-legs and the trunk moved in a backward direction, the animal made an alternative movement backward with the hind-legs, and the moving of the trunk to the left or to the right, was followed by a running movement to left or to the right, of the hind-legs.

Also, if the animal only was supported by one hind-leg, this leg followed the movement of the trunk forward, backward, to the right or to the left, by hopping in the same direction, as the movement of the trunk was made.

If the animal was held in the air by the shoulders, and then was permitted to descend on an oblique plane (with the back-part of its body), the hind-legs adjusted to the inclination of the plane and the animal walked exactly up or down the incline as was desired (fig. 5).

The described hop-movements of the legs play, in normal animals, an extensive part in keeping and in restoring equilibrium. The dog *Robbie* however, if placed, at that time free on his legs, always fell on the ground, because the hopping movements of the hind-legs came much too late and those of the fore-legs were not yet restored.

If, at this stage, the animal was placed on the left side, in its cage, it soon lifted the head and the forepart of the body and remained in a rolled-up position in the manner of a normal dog.

Sometimes the animal tried to take an upright position, but, as the hind-part of the body remained in a reclining position, it turned round in clockwise-movements to the left. Sometimes, the animal succeeded in getting, by

a leap, on its four legs, but always then it fell to the left side. It never lifted the head and fore-part of the body so well from the left side, as it did from the right side.

The animal did not govern well the movements of the head. If it was free in the air, the head fell backward or lateral-ward. If the head was damaged by this movement at the bars of its cage, the animal could whine vehemently.

The restitution of different movements of the extremities in dog *Robbie* as f.i. the hopping movements after trunk-motion, the running backward or foreward of the hind-legs according to trunk-motion — all movements also missing in the first days after cerebellum-extirpation in normal dogs — proves, that they may be restituted without intervention of the hemispheres.

Still other symptoms of the animal are worth mentioning. If chopped-meat was placed in the mouth of the animal, it was well masticated and swallowed. But crusts of bread were rejected from the mouth. And if meat and crusts of bread were given together, the meat was swallowed, the bread-crusts rejected.

If the animal was irrigated with water, it shook itself like a normal dog. If its nose was moistened, the dog licked it off. Tickling of the mucous membrane of the nose was answered by sneezing.

After turning the animal along a dorso-ventral axis, vivid eye-nystagmus is seen.

Interesting was the intense reaction made by the animal on accustic stimuli. The answer to the sharp sound, made by sucking in the air with closed lips, was: adjusting of the auricles, lifting of the head and a movement with the legs. The animal without hemispheres answered this stimulus more intensely, after the removal of the cerebellum than before.

Many tactile stimuli gave vivid reflexes; so the cornea-reflexes were found, as also the movements of the eyelids after touching of the lashes, and movements of the auricles after touching of its hairs.

The animal discharged spontaneously urine and faeces. In the urine neither albumines, nor glucose was found, even in the first days after the cerebellar-removal.

The animal lived in two alternatingly varying periods. In one it was restless, it tried to make walking movements and to lift itself. In the other period it seemed to sleep. If shaken or pinched, it opened its eyes, yawned and moved its hairs as a dog that is awaking.

And lastly it must be mentioned, that the animal, after being set upon its legs, never had "uncontrolled" (LUCIANI's astasia) movements. Those movements do not appear immediately but only after some time, if the cerebellum-removal in normal animals with intact hemispheres has taken place.

Reckoning with the short space of time lived by the animal after the last operation, and with the appearance of an infectious distemper in the third week after it, the conclusion is nearly certain, that the animal has not at all attained the maximum of compensation, and that the possible

restoration of the post-operative phenomena might have been much more evident.

The anatomical annotations upon the dog *Robbie*, are the following.

1⁰. If comparing the rest of *Robbie's* brain with normal brains of a dog, with the naked eye on a photo (fig. 6), it is not only seen that the removed nervous mass is very important, but also that the border lines of the removed hemispheres demarcate the brainstem at the left and at the right side in a very unequal way.

2⁰. It seems that the left hemisphere has been removed more completely than the right one. The remaining part of the right hemisphere surpasses widely that of the left in a frontal direction. The most frontal piece of the right hemisphere is transformed in a spherical mass of nervous tissue, connected with the dorsal wall of the brainstem, which at the right side is nearly twice as broad as on the left side (fig. 6). The cerebellum is taken away on both sides, except a few lateral lamellae only slightly connected by fibres with the brainstem.

3⁰. Research by uninterrupted series of sections gives a solution of the difference between the left and right hemisphere.

At the left side, the striatum has been completely removed with the extirpation of the pallium. On the contrary on the right side, the striatum has been spared. Only at its most frontal end it possibly may be a little damaged.

A more detailed research makes it obvious, that the sphaerical mass of nervous system (fig. 7, N⁰. 27 of the series) contains the dorsally opened frontal end of the lateral ventricle, with its medial and lateral walls. The latter is connected with the striatum (fig. 7, Nos 27 and 69 of the series) in which all the constituant parts, nucleus caudatus, nucleus lentiformis with its putamen and globus pallidus and the nucleus accumbens septi are found. The operating knife has gone lateral to the external capsule towards the olfactory convolutions (fig. 7, Nos 69, 83, 96 of the series).

The striatum is very rich in fibres (fig. 7, Nos 83—111). This may be compared with the status marmoratus, which OSCAR and CÉCILE VOGT have described in pathological cases of the striatum in overfunction.

It is sending out a very strong system of fibres along the "Kammsystem of EDINGER" and the ansa lenticularis (fig. 7, Nos 111 and 126), crossing the capsula interna, wherein the cortical fibres are strongly degenerated but not all lost.

At the left side neither a "Kammsystem" nor an ansa lenticularis is found. Together with the totally removed striatum, they have disappeared at that side.

At the right side a part of the pyriform gyrus with the nucleus amygdalae has remained and from there a certain number of fibres enter well-myelinated in the anterior commissure, that has been totally lost at the left side.

At the left side, the small remainder of the striatum which has been spared (fig. 7, N⁰. 83 of the series), appears as a small field of circular form between brainstem and the left corpus callosum. In this field some fibres appear, being fibres of the capsula interna.

In this way the experimental border-line between removed cortex + striatum and the remaining diencephalon is found (fig. 7, N⁰. 96 of the series) as composed of three parts. In the middle layer is seen the internal capsule, ventrally the cornu AMMONIS with fimbria and columna fornicis, at the dorsal end the corpus callosum, with the sulcus medialis of the hemispheres (fig. 7, Nos 96 and 111 of the series). They are united in a mass of fibres, forming the caudal border of the cicatricial line (fig. 7, N⁰. 111 of the series), where it ends.

The first section, in which no longer operation-lines are passing through the hemispheres is in fig. 7, N⁰. 126 of the series. There it is seen, that all fibres going from the striatum into the "Kammsystem" or ansa lenticularis have fallen out ; neither are they found in more caudal sections. Whereas at the right side those fibre-systems have developed very intensely and are hypertrophied. Dr. MORRISON of Boston is working out the sequences of the loss of those systems at the left side.

However, it may already be mentioned here, that, influenced by the well-preserved striatum of the right side, there are found cell-territories in the middle of the right diencephalon, with well preserved middle-sized and small nerve-cells, missing completely in the left, where the striatum has been removed (fig. 8).

Both diencephala are severely damaged by the removal of both hemispheres and have lost the greater part of their cells. But in the middle of the left diencephalon, in the nucleus medialis and in a medial part of the nucleus ventralis, are seen only holes, where formerly cells have been, while, in the same region of the right diencephalon are found well preserved cells (fig. 8).

To this region the frontal radiation of the red nucleus can be followed (to the diencephalon) and there are reasons for accepting, that at the right side, going from the red nucleus to the thalamus, from there *to the nucleus caudatus* and farther to the nucleus pallidus, the Kammsystem and ansa lenticularis, a system has remained intact and functioning.

At the left side cells in the substantia nigra have disappeared (fig. 9). At the right side (fig. 9), those depending from the striatum, and they are the majority, have all remained, only those depending from the cortex, have disappeared. In the corpus subthalamicum of the left side many of the larger cells in the lateral part have disappeared, while nearly none in the medial parvocellular part of this nucleus are missing.

It would have been of great interest, if the degenerated and fallen out systems between the left striatum and the tegmentum of the pons VAROLI, medulla oblongata and spinalis, as well as the strongly developed paths from the right striatum and the corresponding parts of the nervous system,

had not been complicated by the presence of the cortical and cerebellar pathways. But the animal has not lived long enough to bring a total loss of the cortical and cerebellar fibres.

This may be illustrated by the study of the restiform body and the brachium pontis of the dog *Robbie*, compared to those parts in animals living 136 days or 360 days without a cerebellum.

In all those animals the cell-preparations of the nervous system do not differ very much. In the spinal cord, large cells in the posterior horns and most in the columns of CLARKE are all degenerated after 38 days, and after 136 days or 360 days have all disappeared. In the medulla oblongata in all cases the cells are degenerated and most of them have disappeared in the nuclei olivares inferiores, the nuclei funiculi laterales, in the nuclei proprii corporis restiformis, together with some of the smaller cells in the nuclei of GOLL and BURDACH. In the ventral formation of nuclei in the pons VAROLI all cells have disappeared after 38, 136 and 360 days.

But fibre-preparations differ intensily of cell-preparations after 38 days or longer, because the degeneration of fibres follows the degeneration of cells, but the loss of fibres follows the loss of cells in a much slower tempo.

In dog *Robbie*, WEIGERT-preparations give the impression that the corpus restiform and the brachium pontis are unaltered.

After 136 and 360 days all fibres in the restiform body have disappeared except the long dorsal spino-cerebellar pathway, which never disappears totally.

And the brachium pontis in *Robbie*, seems to have no fibres missing, it contains all fibrae transversae and all fibrae rectae pontis, whereas after 136 or 360 days, all fibres in the brachium pontis, together with the fibrae transversae et rectae, have disappeared with the cells.

We have not been able to have in *Robbie*, the fibre-systems of the right striatum, well developed but un-complicated, because not all cortical and cerebellar fibres had been destroyed. This would have been possible, if the animal had lived longer.



Fig. 1. The dog *Robbie*, after removal of both hemispheres of the brain. Exposition on the 5th of February 1927.



Fig. 2. Absence of reflexes of posture after removal of both hemispheres of the brain. If the head or the ventral surface of the body were touching a table, the extremities were not placed upon the table.

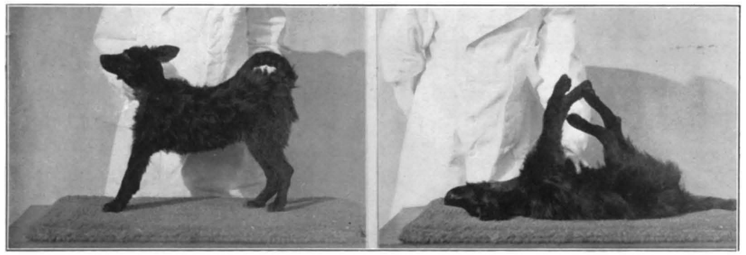

Fig. 3. The dog *Robbie*, one week after the removal of the cerebellum. The animal has extension-tonus of the extremities on both sides. Exposition on the 13th of February 1927.



Fig. 4. 1. The hind-legs are bending at a pressure upon the soles of $1^1/_2$ kilogram.
2. The fore-legs resist bending at a pressure upon the soles of 11 kilogram.
3. If a sandbag of $5^1/_2$ kilogram is hung on the shoulders of the animal, the fore-legs do not bend. Weight of the dog $6^1/_2$ kilogram.

Exposition on the 13th of February 1927.



Fig. 5.

1. The animal is lowered with the hind-part of its body upon an inclined plane.
2. The animal does not sit, but, by moving its legs backward, it tries to remain standing and walks down the inclined plane.

3 and 4. Here also the animal is lowered with the hind-legs upon an inclined plane. It again tries by moving its legs backward to keep from sitting and so walks backward up the inclined plane.

Exposition on the 23th February 1927.

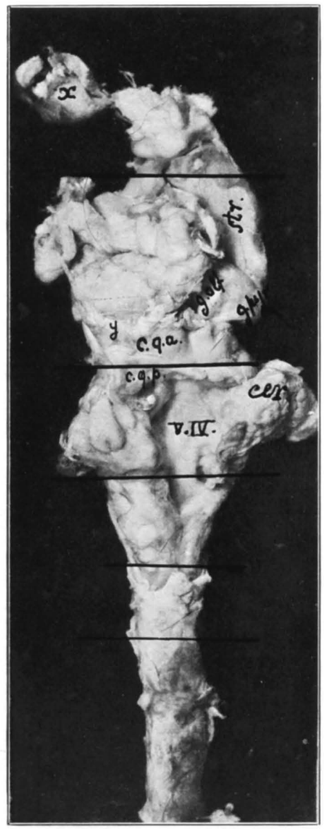

Fig. 6.
The rest of the brain of the dog *Robbie* seen from a dorsal view.

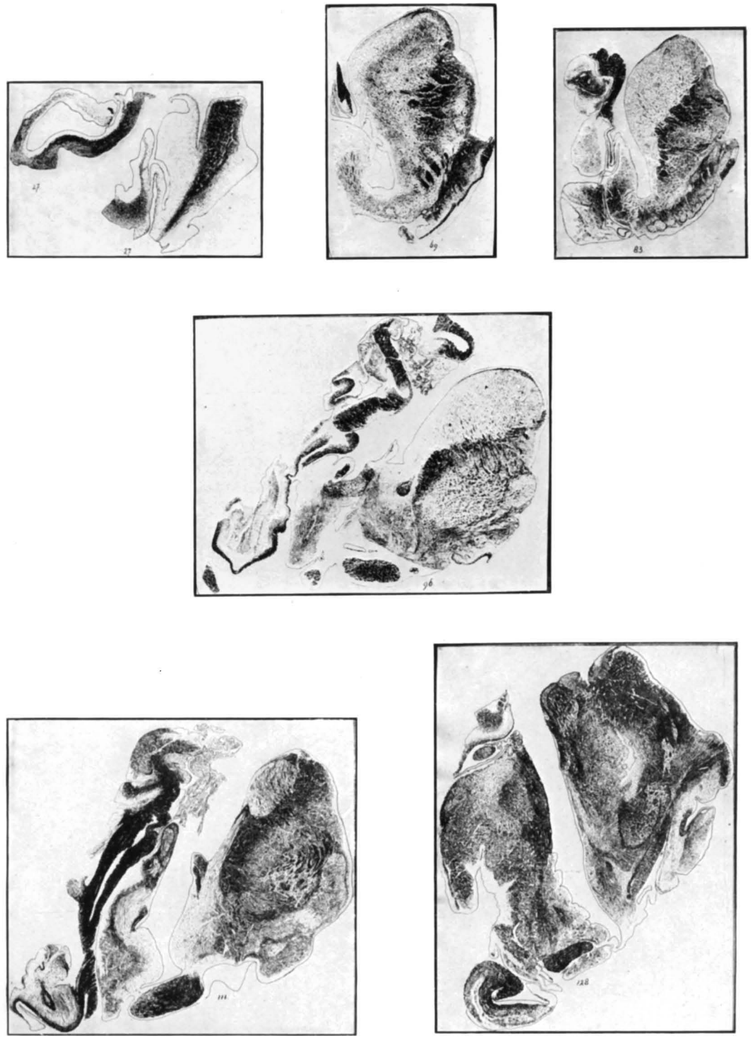

Fig. 7.
6 drawings of sections through the frontal end of the brain of dog *Robbie*.
At the left side the striatum is removed.
At the right side the striatum has been nearly totally spared.

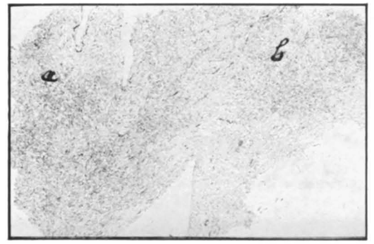

Fig. 8.
Transverse section through the commissura media thalami.
At the left: in *a*. total degeneration of cells in the medial part of the thalamus.
At the right: in *b*. several well preserved cells are found in that medial part.

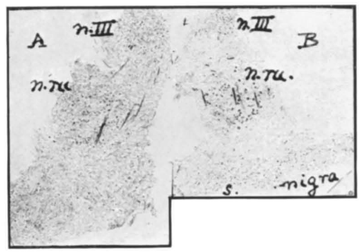

Fig. 9.
Two sections through the pedunculus cerebri.
A. At the left: loss of nearly all cells in the substantia nigra.
B. At the right: nearly all cells in the substantia nigra are well preserved.