Anatomy. — *Further communication on the fissures of the frontal lobes in Neanderthal men.* By C. U. ARIËNS KAPPERS.

(Communicated at the meeting of January 26, 1929).

In the meeting of December 22nd 1928 I gave a description of the fissures on the frontal lobes of Pithecanthropus erectus Dubois, comparing them with those of the Chimpanzee, Neanderthal- and recent men. In the present communication I shall compare the frontal lobes of different Neanderthal men with one another, publishing at the same time the drawings, made by the scientific artist Mr. CHR. VLASSOPOULOS, of some Neanderthal casts.

I shall discuss the s. frontalis superior, medius and inferior, their relation to the precentral fissures, the intermediate fosset (8), and add a few remarks concerning the inferior marginal part of the frontal lobe.

The *s. frontalis superior* [1]) gives very few impressions in Neanderthal-casts, especially on the caudal part of the frontal lobe. This fits in very well with SCHWALBE's [2]) and SYMINGTON's [3]) experiences with the casts of recent men, from which appeared that the impressions of the convolutions and the juga caused by grooves are less pronounced proceeding from the bottom of the frontal lobe to its dorso-caudal surface.

On the La Chapelle cast there is even no indication at all of a superior frontal fissure. On three casts, however, those from Düsseldorf (left and right), La Quina (left) and Rhodesia, a large part of this fissure is indicated.

In anthropoids the frontalis superior may or may not be connected with the superior precentral fissure (see fig. 5 of my first communication). It may moreover be interrupted in its own course. The same is observed in adult Europeans. Which of these conditions prevails in Neanderthal men is difficult to say on account of the lack of impressions.

Only on the Düsseldorf Neanderthal [4]) and the Podbaba man (left

---

[1]) Of a sulc. fronto-mesialis (CUNNINGHAM), so often occurring in recent men, and occasionally in anthropoids (separate dimples medially to the superior frontal fissure) no races are observed on the casts. Its very dorsal position apparently prevents this.

[2]) SCHWALBE. Ueber die Beziehungen zwischen Innenform und Auszenform des Schädels. Deutsches Archiv f. Klin. Medizin, Bnd. **73**, 1904.

[3]) SYMINGTON. On the relations of the inner surface of the cranium to the cranial aspect of the brain. Sir JOHN STRUTHERS lecture. Edinburgh medical Journ. 1915 and Endocranial casts and brainform: a criticism of some recent speculations. Journ. of Anat. and Phys., Vol. **50**, 1916. (See, however, also BOULE and ANTHONY, Ibid. Vol. 51, 1917).

[4]) On the left hemisphere the supposed connecting fissure of the frontalis superior with the precentral is only indicated by its lateral wall. i. l. by the mid-frontal convolution. The impression of its medial wall, the superior convolution is flattened. — In the Podbaba cast (left) the latter convolution seems to be indicated.

hemispheres) a connection of the frontalis superior with the precentral is slightly indicated.

It is, however, quite possible that the superior frontal fissure extended caudally beyond this point as it may do in recent men.

On the other hand, the second characteristic of the frontalis superior — the interruption in its course — is clearly present in some casts.

Even in Pithecanthropus (right hemisphere) this fissure becomes less deep about the level where it is approached by 7e (cf. fig. 1, first communication).

Although its more shallow character at that level is evident, I have no reason to accept that a real interruption occurred here, the less so as the brain fissures were of course deeper than those on the cast.

It is, however, interesting that at the same level there is a distinct interruption of this endocranial groove in the Düsseldorf man (left and right). The same seems to occur on both sides of the La Quina cast. Although this interruption may also occur in anthropoids (see fig. 5 of my first communication and EBERSTALLER's [1]) figures 7 and 8), it is especially frequent in recent man. CUNNINGHAM [2]) even distinguished two parts in the superior frontal fissure, a frontal accessory part and a main hind part, which often originate separately in ontogenesis. Evidently the same distinction can be made in Neanderthal men.

A third point in its morphology are the connections of this fissure with the s. frontalis medius : the rami connectentes, which may proceed as well from the main part of the frontalis superior as from its frontal accessory part (about the level of 7*b*).

CUNNINGHAM observed the latter in 44 % of his Irish brains (l.c. p. 69). Also these connections are not specifically human, they are observed as well in anthropoids as in DUBOIS' ape man. That in the Neanderthal-casts the indications of such connections are only rare, is not strange since the impressions at this level are generally vague, and these connections moreover are less deep than the superior frontal itself. Traces of it are observed on the right hemisphere of the Düsseldorf man (at 7*b*) and at the same spot in the Rhodesian by a dorsal branch of 7. It is, however, difficult to say whether these branches reached the superior frontal.

The impressions of the *sulc. frontalis medius* are much more evident than those of the former. Still this groove is realized in recent men only much later than the superior and inferior frontal fissure (by EBERSTALLER in 1890, p. 72). In his description this author says that this groove "in seiner typischen Gestalt" does not join the precentral but only begins

---

[1]) EBERSTALLER. Das Stirnhirn. Ein Beitrag zur Anatomie der Oberfläche des Groszhirns. Urban u. Schwarzenberg Wien u. Leipzig, 1890.

[2]) CUNNINGHAM. Contributions to the surface anatomy of the cerebral hemispheres with a chapter on cranio-cerebral topography. Memoires N⁰. VII, Roy. Irish Acad. Dublin 1892.

(usually by a transverse piece) quite a distance in front of it. It is different in Neanderthal men. In all my casts its connection with the precentral (mostly the inferior) seems to exist. On the La Quina left hemisphere it connects with the superior precentral, a condition that may also occur in KEITH' Gibraltar cast and in recent men.

Concerning anthropoids I must confess that this fissure is very often described (recently again by MINGAZZINI [1]) as S. frontalis inferior. This is caused by the fact that the frontalis inferior in anthropoids may fail, or — on account of its steep course in those animals (see fig. 5 of my first contribution) — is not recognized as such, and their sulc. medius, often connected with the precentral reminds one of the frontalis inferior of men.

EBERSTALLER came nearer the truth when he compared the sulc. rectus of monkeys and apes with the frontalis medius of men, although I am more inclined to consider the rectus as a forerunner of the fronto-marginal fissure, which, however, is very frequently continuous with the frontalis medius (cf. also KEITH: Report on the Galilee skull, 1927, p. 103).

In the Trinil cast where all frontal sulci are clear in their arrangement and form a splendid base of interpretation, the frontalis medius (7) is also continuous with the inferior precentral (5) and can be also distinguished from the fronto-marginal (9).

In the Neanderthal men the medius has the following characteristics: Everywhere where the region in which it lies is well expressed. It is continuous mostly with the inferior precentral or with the superior [2]) precentral. The latter is indicated on the left hemisphere of the La Quina cast, where consequently the mid-frontal sulcus runs ventro-frontally in its initial course. In all other casts the frontalis medius (7) in its initial course shows a dorsal curve (6), immediately in front of the inferior precentral. This curve may continue with a ventral branch (6′) which is hardly (or not) indicated on the right hemisphere of the Düsseldorf Neanderthal men, that thus resembles the relation in the ape-man (fig. 1, right hemisphere of my first contribution), and the Chimpanzee (fig. 5, left hemisphere, ibidem) very strikingly.

The ventral branch 6′ is, however, well pronounced on the left hemisphere of the Düsseldorf and La Chapelle Neanderthal man and on the right side of the Rhodesian and probably of the La Quina cast.

A similar branch (6′) is very frequent in recent men. It even occurs on EBERSTALLER's scheme where it is represented, not nominated, as a triradiate sulcus between his F. 2, and the top of his p.c.i. But here, as often in recent man, the connection of 6 with the inferior precentral is inter-

---

[1]) MINGAZZINI. Beiträge zur Morphologie der äuszeren Groszhirnhemisphärenoberfläche bei den Anthropoiden (Schimpanse und Orang). Archiv f. Psychiatrie und Nerven Krankheiten, Bnd. **85**, 1928.

[2]) This also may occur in recent men. See LANDAU: Ueber die Furchen an der Lateralfläche des Groszhirns bei den Esten. Zeitschr. f. Morph. u. Anthrop. Bnd. **16**, 1913, p. 248.

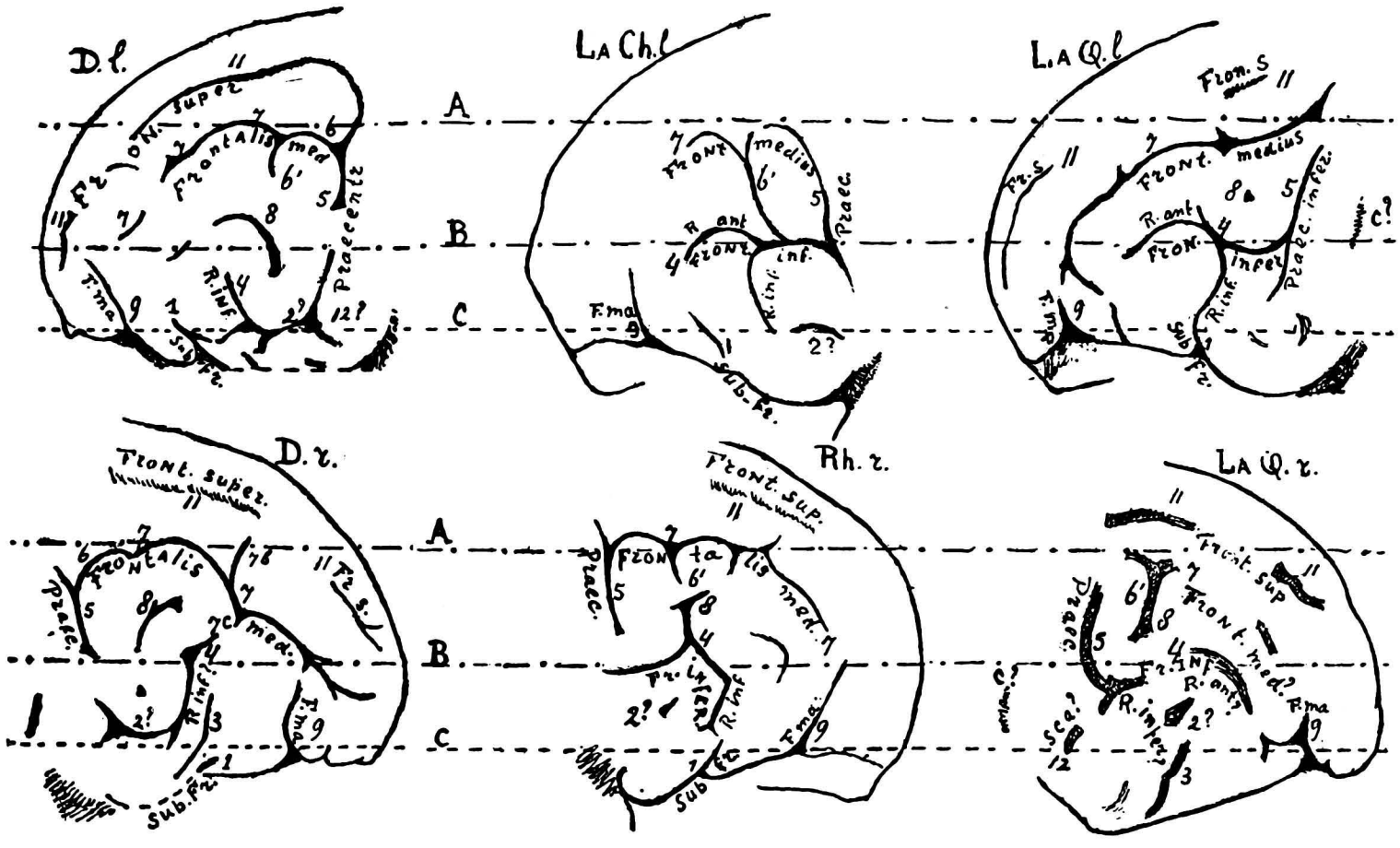

Fig. 1. Fissures on the frontal lobes of the Neanderthal man from Düsseldorf (D.), La Chapelle aux Saints (La Ch.), La Quina (La Q.) and Rhodesia (Rh.) : l = left hemisphere, r = right hemisphere.

rupted (see also WINKLER [1]) and LANDAU, l.c.). In other cases it is connected with the superior precentral (see fig. 4 of my former contribution).

As, however, the connection of the frontalis medius with the inferior precentral is also frequent in Chimpanzees, and even very pronounced on both sides in the ape man of Trinil, this condition, prevailing in Neanderthal men must be considered as more primitive than in recent men. I am inclined to believe that the interruption of its connection with the inferior precentral and its eventual attachment to the superior precentral, so frequently observed in recent men (fig. 4, l.c.), is a result of the considerable development of the convolution underneath it, the foot of the second frontal gyre, the development of which in recent men in comparison with Neanderthal men I already (l.c.p.) emphasized on account of other reasons.

The medial frontal fissure is further characterized in Neanderthal men by a second curve finishing at 7c in the Düsseldorf cast (D.r.). Then it proceeds frontally eventually approaching the interhemispherial cleft with the medial branch of a bifurcation, the lateral branch of which turns in the direction of the fronto-marginal. These relations are similar in Pithecanthropus and in recent men, where the frontalis medius may continue in the fronto-marginal.

Eventual connections between the medial and superior frontal are discussed above.

Also indications or tendencies of connections with the inferior frontal sulcus occur, so in the Düsseldorf man on the right hemisphere at 7c as in the Rhodesian between 6′ and 8, in the La Chapelle man at 6′.

It is very remarkable that the mid-frontal sulcus, whose existence in present races is only so recently realized (vide supra) and which is mostly broken into pieces in the Javanese (KOHLBRUGGE [2]), l.c. p. 82), while SERNOFF [3]) could state its occurrence in only 17 % of his Russians, is such a constant and continuous groove in Neanderthal men, where nobody can doubt its existence, and where also ANTHONY [4]) rightly described its occurrence in the La Quina cast, and equally observed its relation to the fronto-marginal fissure. KEITH found this connection even indicated on his Australian cast (Antiquity of Man, 7th Ed., Vol. II, fig. 222).

Before proceeding to the inferior frontal sulcus I have to say a few words concerning the *intermediate fosset* or fissuret 8, lying between the

---

[1]) WINKLER. The relative weight of human circumvolutions. PETRUS CAMPER Deel 1, 1902 Plate 1 fig. 2. (sulc. frontalis intermedius).

[2]) KOHLBRUGGE. Die Gehirnfurchen der Javanen. Eine vergleichend-anatomische Studie. Verhandl. d. K. Ak. v. W. Amsterdam, 1906 Sectie II: "Ein eigentlicher S. frontalis medius fehlt den Javanen. Im Gyrus frontalis medius seht man statt dessen fast nur transversale Furchen."

[3]) SERNOFF (russian), quoted from LANDAU l.c. supra.

[4]) ANTHONY. l'Encéphale de l'homme fossile de La Quina, Bulletins et mémoires de la Soc. d'Anthropologie de Paris, Mars, 1913 (p. 158, fig. 10).

middle and inferior frontal fissure. I have already pointed out that fosset 8 also occurs in the Trinil cast (l.c. right hemisphere fig. 1), and that analogous intermediate fossets may occur in recent men. In the Neanderthal man of Düsseldorf this fosset is enlarged to a fissure that ends in the middle of the missing connection between the frontalis inferior (4) and precentralis inferior (5), in which connection it continues in the Rhodesian, I found an exactly analogous condition in an Australian aboriginal's brain.

On the La Quina cast (right hemisphere) this fosset seems to continue in the mid-frontal sulcus (7) by means of 6'. The relations are, however, not clear enough here to provide full certainty about this. The same configuration is, however, observed by ANTHONY (l.c. p. 162, fig. 11).

Besides already in the Chimpanzee (right hemisphere fig. 5 of my first paper) this fosset connects as well with the inferior as with the mid frontal sulcus.

Concerning the constituents of the *inferior frontal* sulcus in recent men different opinions exist.

EBERSTALLER (l.c.) whose ideas are shared by RETZIUS stated that this sulcus is generally connected with the inferior precentral and ends after a frontal curve as an axial groove of the frontal or triangular operculum (cf. fig. 4 of my former contribution).

Frontally to this axial groove lies his *radiatus*, that may or may not be connected with it. According to ECKER [1]), SCHWALBE [2]) and KOHLBRUGGE (l.c.), however, we have to consider the whole curve including the radiatus and its branches as inferior frontal sulcus. I fully agree with KOHLBRUGGE's conception (l.c. p. 91) : "Er geht vom Präcentralis aus oder entsteht nahe an der Stelle, zieht dann zunächst in sagittaler Richtung nasalwärts, krümmt sich in Bogen oder mit scharfer Ecke ventralwärts und bildet so die Basis der Pars triangularis. Er kann den orbitalen Rand erreichen oder sich nochmals und zwar caudalwärts krümmen und den ganzen Ramus anterior fossae Sylvii mit einem Halbkreis umgeben." Such is also the most frequent relation of this sulcus in the European brains I examined.

I must, however, add to this that the large continuation of this system in nasal direction seems to be typical specially of recent men as appears from a comparative study of anthropoids, Pithecanthropus, Neanderthal and recent men.

As I pointed out before in my Chimpanzees the inferior frontal sulcus [3])

---

[1]) ECKER. Die Gehirnwindungen des Menschen. Braunschweig 1869.

[2]) SCHWALBE. Lehrbuch der Neurologie. 1881.

[3]) EBERSTALLER considered the fronto-orbital of anthropoids as the homologue (l.c. p. 119) of the human inferior frontal, although he remarks himself „Befremden könnte erregen dass die Furche zur Hälfte auf der Orbitalfläche gelegen ist" (l.c. p. 119), — while the inferior frontal in men never comes on the orbital surface. In my specimens of Troglodytes niger both the fronto-orbital and behind it the inferior frontal are present. Also KOHLBRUGGE contested EBERSTALLER's view. MINGAZINNI only describes two frontal fissures a superior and on infimus. The latter is, however, homologous to the human midfrontal. He overlooked the rather steep anthropoid homologue of the human frontal's inferior.

runs steeply downward after its origin from or very near the inferior precentral, reaching the orbital operculum or lateral inferior margin of the frontal lobe behind the indentation of the fronto-orbital sulcus. In Pithecanthropus it runs less steep, more obliquely, so that the inferior frontal convolution has enlarged specially on the right. At its end a small axial groove (3) of the orbital operculum appears. In Neanderthal men its curve runs still more horizontally and the inferior convolution again enlarges. The Rhodesian shows a simple relation, having only one curve, which, however, is higher and at its beginning runs more horizontally than in the ape-man. In the other Neanderthal casts the condition is less simple than in the Rhodesian [1]). The fissure shows a gradual development in the La Quina and La Chapelle (left hemispheres), and probably in the *Podbaba* cast. This development exists in a further nasal outgrowth by means of a frontal branch, perhaps indicated in the Rhodesian by a small curved fissure just before the place where the inferior frontal joins the intermediate fosset 8 (not denominated in fig. 1 Rh. r.). In the other casts, this fissure continues in the inferior frontal and forms its anterior curve or ramus anterior that may continue frontally beyond the level of the *subfrontalis* (1). This extension beyond the level of the subfrontalis fails in the Trinil cast and in anthropoids, although a double curve is indicated in the former. It may occur in recent man but the subfrontal itself may also extend correspondingly frontally here so that its anterior end may correspond again with the anterior curve of the inferior frontal fissure (see fig. 4 of my first contribution). Since in recent men the frontal curve very often runs further downward than indicated on Neanderthal casts it may again connect with the elongated axial groove of the orbital operculum (3).

In the Düsseldorf cast the r. ant. frontal. inf. is wanting on the right [2]) and on both sides the first dorsal curve shows an interruption by two bridging convolutions, the caudal one of which runs just before the inferior precentral (between this and the intermediate fissuret 8), while the anterior bridging convolution runs before fissuret 8.

This also explains why the simple fosset, that usually is 8, is changed in a curved groove, since it now lies between two parallel bridging convolutions

These bridging convolutions between the inferior and mid frontal convolution are also observed in recent men, mostly as "Tiefenwindungen", but EBERSTALLER (l.c. p. 66)

---

[1]) That the simpler relation seems to occur in the Rhodesian, whose skull capacity according to WOODWARD SMITH is 1280 cm^3, and whose encephalic index is 80,6, may be accidental, although it is interesting that RAMSTRÖM considers this the most primitive human skull hitherto found, equally primitive probably as the Heidelberg jaw. ELL. SMITH, also considers the Rhodesian as more primitive, and so does Sir ARTHUR KEITH. See RAMSTRÖM. Ueber die älteste Steinkultur in Afrika und Asien etc. Nova acta R. Soc. Scient. Upsaliens 1927, p. 27, ELL. SMITH, Rhodesian man and associated remains. Brit. Mus. Publ., 1928 p. 53. ARTHUR KEITH. The antiquity of man, 7th edition. I found a similar arrangement of the inferior frontal sulcus on the right hemisphere of an Australian aboriginal's brain, while KEITH's fig. 29 of his report on the Galilee skull (l.c. infra) shows an analogous condition on the left side of an Australian's endocranial cast.

[2]) On the left it may be indicated by a small fissure, frontally continuing (virtually) the course of 8.

observed the posterior bridging convolution in a superficial position in 24 % of his brains. The anterior bridging convolution was also observed by him (vorderste Tiefenwindung), but he does not say how often he saw it in a superficial position. Similar variations are described by CUNNINGHAM, KOHLBRUGGE, and APPLETON [1]) (l.c. see fig. 4 and p. 96). In APPLETON'S Tamil, the inferior frontal also shows that ascending branch in the direction of the mid frontal fissure, occurring on the right side of the Düsseldorf cast (between 4 and 7c).

The axial groove (3) on the right Düsseldorf hemisphere has become independent of 4. In recent men it is nearly always independent from the perpendicular branch of 4 (that may form the S. axialis operc. frontalis), as is easily explained by the development of the anterior horizontal branch of the fossa Sylvii, which separates the axial branch of the triangular operculum from the orbital operculum. On the other hand, groove 3 may extend frontally in recent men and connect with the descending branch of the second curve (l.c. fig. 5), a condition not hitherto observed in Neanderthal casts where the second arch of the frontalis inferior does not show that large ventral extension (see the preceding page).

Consequently, although the enlargement of the inferior frontal convolution in Neanderthal men compared with the Trinil cast and anthropoids is striking, we have no sufficient evidence that it has attained the extension of recent men, although — on the left hemispheres especially — the relations approach those of recent men.

Besides in Neanderthal casts only very vague and incomplete impressions are found on the gyrus frontalis inferior, where in recent men the rami anteriores f. Sylvii, the diagonal sulcus, and a ventral continuation of the inferior precentral are very common features. Only on the La Quina and Düsseldorf cast (left hemispheres) indications of a ventral extension of the inferior precentral are found. Of a diagonalis no trace is seen and of the rami anteriores fossae Sylvii never more than a trace (2 ?) of one groove [2]) is observed. This groove sometimes resembles a horizontal branch [2]).

I have, however, already pointed out in my first contribution that we should refrain from rapid conclusions here since SYMINGTON showed that, in recent men especially, this part of the skull never gives impressions. Still it would not be impossible if a ventral elongation of the inferior precentral and a diagonal sulcus were poorly developed in Neanderthal men, as they also fail in the so deeply impressed Trinil cast. Similarly it is not excluded that a single ramus anterior f. S. was a frequent condition, considering the fact that this is also the case in Pithecanthropus, and in 27 % of recent men, where CUNNINGHAM even found it in 41 % on the right side.

BOULE and ANTHONY considered it possible that my groove 1 might be

---

[1]) APPLETON. Description of two brains of natives of India. Journ. of Anat. and Physiol. Vol. **45**, 1911 (fig. 4 and p. 96).

[2]) It may be that on the right hemisphere of the Düsseldorf cast the small dimple, lying above 2? is a remnant of a ram. anterior ascendens f. S. Then 2? would be a ram. horizontalis f. S.

the anterior horizontal branch, but rejected this supposition [1]). Fissure 1 is doubtlessly homologous to the fronto-orbital of apes (cf. also KEITH).

Concerning the grooves indenting the orbital margin I may be short since these relations are amply described in my former paper. They are the *fronto-marginal sulcus* (9), extending in the direction of the mid-frontal fissure (7) sometimes perhaps continuing with it as often occurs in recent men. I also pointed out that 1, the s. *subfrontalis* mihi is the homologue of the fronto-orbital of apes and may also occur in recent men, though usually smaller. It is best developed in the Rhodesian [2]) (see fig. 3 of my first contribution), where it strongly reminds us of the fronto-orbital of such Chimpanzees, where its extent on the convexity has been already reduced, which occurs more often in the Chimpanzee than in Orangs.

Resuming my results I conclude :

1⁰. that the fissuration in Neanderthal men is more humanoid than in Pithecanthropus, and that it differs from the relations in recent men ;

2⁰. by the fact that Neanderthal skulls may give more impressions on the endocranial cast than recent skulls do, though less than in Pithecanthropus. In this respect both differ from anthropoid casts where hardly any impressions are visible on the frontal lobe [3]).

3⁰. by the strong development of the mid-frontal fissure, which is predominant in the relief of Neanderthal casts, and more primitive (more pithecanthropoid) in its character than in recent men, where it is mostly divided up into pieces, probably in consequence of the greater development of the foot of the mid-frontal convolution (see my first paper).

4⁰. by the fact that this groove in all casts I examined seems continuous with the precentral groove (mostly the inferior) which according to EBERSTALLER only occurs in the minority of Europeans ;

5⁰. probably by a somewhat lesser development of the anterior part of the inferior frontal convolution and sulcus.

I will not end without adding a few words concerning SYMINGTON's criticism (l.c.) on the work of BOULE, ANTHONY and ELL. SMITH, the reliability of which he doubted on account of the failing impressions on endocranial casts of recent men. I do not doubt the accuracy of SYMINGTON's results in recent men, the less so as also the cast of the Aurignac Homo sapiens fossilis (in contrast to the Predmost cast ; TILNEY and RILEY [4])) shows no impressions whatever on the frontal lobe. This, however, gives us

[1]) BOULE and ANTHONY Neopallial morphology as studied from endocranial casts of fossil men. Journ. of Anat. and Phys. Vol. **51**, 1917.

[2]) In an australian aboriginal's brain, which I had the opportinity to examine, this sulcus was just as strongly developed on both sides as in the Rhodesian.

[3]) In this respect also the ape man of Java approaches more the Neanderthal men than the anthropoids do.

[4]) See their photographs and description of this cast in "The brain from Ape to Man". Vol. **2** fig. 408—414 and p. 918—922.

C. U. ARIËNS KAPPERS: FURTHER COMMUNICATIONS ON THE FISSURES OF THE FRONTAL LOBES IN NEANDERTHAL MEN.

PLATE I.

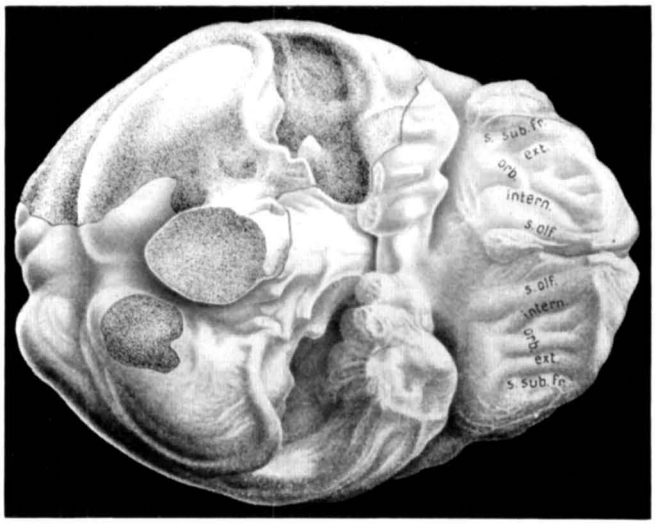

Fig. 1
Basal aspect

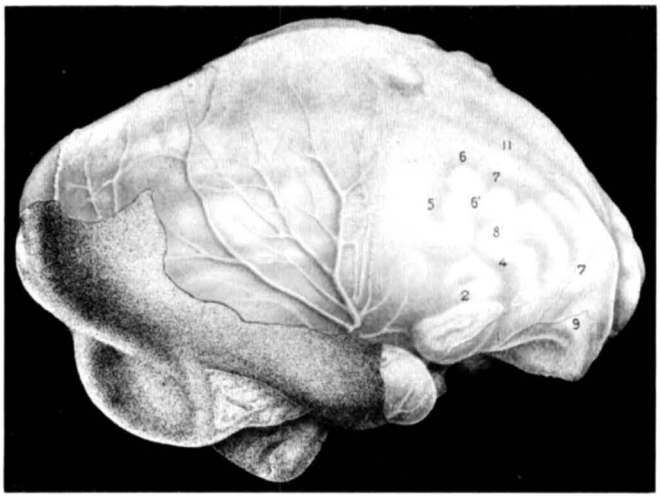

Fig. 2
Right hemisphere

Endocranial cast of the Rhodesian skull. — 9 in fig. 2 refers to the sulcus behind it.

C. U. ARIËNS KAPPERS: FURTHER COMMUNICATIONS ON THE FISSURES OF THE FRONTAL LOBES IN NEANDERTHAL MEN.

PLATE II.

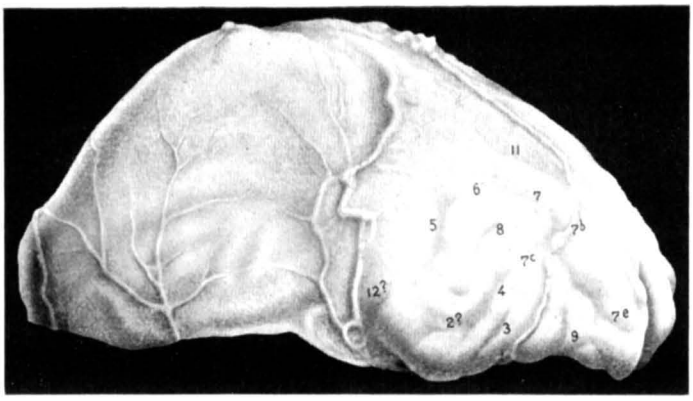

Fig. 1
Düsseldorf
cast

Fig. 2
La Quina
cast

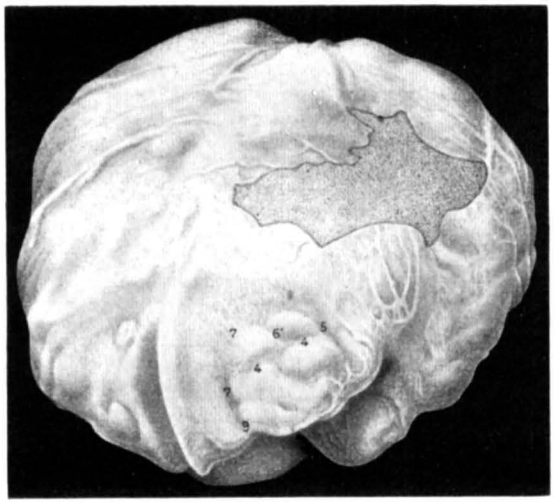

Fig. 3
La Chapelle
cast

For the identification of fissure 1 in the La Chapelle cast see textfigure 2.

no right to doubt the value of impressions occurring on Neanderthal casts, the less so since they are still more pronounced in the ape man from Java, and can be easily correlated with the latter.

The question is: why are the endocranial impressions more pronounced in the Neanderthal and ape-man than in Homo recens?

According to SCHWALBE they are present in all animals except the Orang Utan, Chimpanzee and Gorilla (l.c. p. 382) and in newborn children are indicated, though slightly, on nearly all the skull bones (l.c. p. 380).

Apparently a special pressure on the skull is responsible for this. This may also explain their constant appearance on the orbital surface in the erect going men, even in recent men.

That the impressions on the frontal lobes in Neanderthal casts may be trustworthy guides for studying the fissuration is, moreover, confirmed by the fact that their study, combined with that of the Pithecanthropus impressions yields such conclusive results, as shown in this and my former paper. I may add that this also appears from the studies of Sir ARTHUR KEITH [1]) on the Piltdown and Australian endocranial casts (l.c. Vol. II, fig. 221 and 222) where this author also found indications of the frontal fissures and from his studies on the Galilee and Gibraltar casts [2]). His conclusions in several aspects agree with my results, obtained before I had any knowledge of those of KEITH, and by the study of other casts than those used by the English anthropologist.

It is a great satisfaction to me not only to confirm several of BOULE and ANTHONY's and KEITH's results, but to extend their data and correlate them with the relations in the ape man of DUBOIS.

EXPLANATION OF FIGURES:

1 = fronto-orbitalis or subfrontalis mihi..
2 = ramus anterior fossae sylvii.
3 = axial groove of the orbital operculum.
4 = frontalis inferior.
5 = precentralis inferior.
6 = connection between the latter and the frontalis medius.
6′ = ventral branch of the frontalis medius.
7 = frontalius medius.
8 = intermediate fosset of the midfrontal convolution.
9 = fronto-marginal.
10 = sulcus bordering the rostrum.
11 = frontalis superior.
12 = subcentralis anterior;
c = ventral end of the centralis.

---

1) KEITH. The antiquity of man. 7th Edition, 1928.

2) KEITH, A report on the Galilee skull. Publications of the British school of Archaealogy in Jerusalem, 1927.