ZOOLOGY

ABSORPTION OF TOOTH TISSUE IN THE SPERM WHALE

BY

H. BOSCHMA

(Communicated at the meeting of February 25, 1950)

According to COLYER (1936, p. 638) in chronic inflammatory processes of the parodontal tissues there is often some absorption of the root of the tooth. As examples of this phenomenon he describes and figures a tooth of a Killer Whale (*Orcinus orca* (L.)) and one of a Sperm Whale (*Physeter macrocephalus* L.). Of the latter COLYER (loc. cit., p. 639) states:

"The tooth of a Sperm Whale, Fig. 864 B, shows a large area of absorption limited to one side of the root. The pathological process causing the loss of tissue was probably associated with pressure from the adjacent tooth. Martin A. C. Hinton, who has a wide knowledge of the Cetacea, informs me that the teeth are set loosely in their sockets and can be moved easily. It is not unusual in these animals for a tooth to be brought into close contact with its neighbour and is therefore possible when this occurs that foreign bodies may become lodged between the teeth and so start pathological processes in the periodontal membrane leading to absorption of the hard tissues. The condition in this tooth of a Sperm Whale is very similar to that seen in human teeth from pressure of one tooth on another, a typical example being the absorption of the root of a mandibular second molar by the crown of a misplaced third molar."

As in other Cetacea the teeth of the Sperm Whale are set loosely in their sockets of the lower jaw, but by no means they can be moved easily. The roots of the teeth of the Sperm Whale are firmly embedded in a very hard and strongly fibrous gum which immovably fixes them to the jaw. Moreover, the individual teeth are implanted in the jaw at distances from each other equalling their thickness, so that it is altogether impossible for two adjacent teeth to come into contact. The firmness of the gum of the Sperm Whale is well illustrated by a case mentioned by NEUVILLE (1932, p. 305, pl. XII), in which the gum was left on the lower jaw to keep the teeth fastened to the jaw in their original position, but after desiccation and contraction of the gum the latter pulled the teeth out of the jaw.

The area of absorption on one side of the root of COLYER's specimen therefore cannot have been caused by pressure of an adjacent tooth. It remains, however, possible that friction by an antagonistic tooth, one

of the more or less rudimentary teeth as they not unfrequently occur in the upper jaw of the Sperm Whale, was the primary cause of the inflammation that gave rise to the described absorption. But COLYER's figure does not show anything pointing to a facet caused by a regular contact of this mandibular tooth with an antagonist in the maxilla.

A Sperm Whale tooth in the Nantucket Museum, described by POUCHET and BEAUREGARD (1889, Pl. VI fig. 3), in nearly every respect is similar to the specimen dealt with by COLYER. On one side of this tooth there is a distinct area of absorption, whilst the inflammation at the basal part of the root has given rise to a thickening of this region. The cited authors describe the tooth as "fortement cariée", without giving the reason why they come to the conclusion that this abnormality was caused by caries. The figure does not show any indications of a former contact of the tooth with another.

The three Sperm Whale teeth described in the present paper are in the collections of the Leiden Museum. They were selected from material brought together by whaling cruises some time before the last war, probably in the antarctic region. The teeth dealt with here show peculiarities of absorption similar to that in the teeth described by COLYER and by POUCHET and BEAUREGARD. In one (fig. 1) the factors influencing the abnormality are not apparent, in each of the two other teeth (figs. 2 and 3) the inflammation obviously was brought about as a result of contact with an antagonistic tooth in the upper jaw.

Judging by its comparatively large size the first tooth (fig. 1) is from a male Sperm Whale. Its total length is 143 mm; in all probability in the living animal about one third of the tooth protruded from the gum. The topmost part is evenly rounded by wear, so that here a blunt cone of dentine has lost its covering layer of cement. The figure in all probability shows the lingual side of the tooth. With the exception of the top and the lower part of the root this side of the tooth is covered by a dark layer in which some irregular white patches are visible, indicating that here the parodontal tissues have undergone inflammatory processes. At the labial side of the tooth the same abnormal state is present though to a less extensive degree. The pathological process resulted in weakening and partial absorption of the root. Moreover, inside the pulp cavity the absorption of tooth tissue continued upwards, so that the tooth now has a wide central cavity extending for 73 mm from the lingual base of the root (for 113 mm from the labial base of the root).

After the process of absorption of the root had set in, the lower part of the root partly regenerated, resulting in more or less irregular outgrowths of tooth tissue around the area of inflammation.

As stated above the abnormality of this tooth is of a similar kind as that previously described by other authors; the cause of the process is unknown. There is at least not any indication of a contact of this tooth with an antagonist in the upper jaw.

Maxillary teeth of the Sperm Whale have been mentioned or described in a more or less detailed manner by several authors (cf. BOSCHMA, 1938, pp. 207—225). In some papers, moreover, phenomena of wear of mandibular teeth have been described which must have been due to contact of these teeth with their antagonists in the upper jaw. Beautiful examples of this kind were described and figured by NEUVILLE (1932, p. 326, figs. 50—53); the large facets occurring on these teeth must have been brought about by friction of a maxillary tooth against their crown. Similar facets are found on some of the teeth of the lower jaw of a female Sperm Whale in the Leiden Museum (BOSCHMA, 1938, figs. 17 and 18). In the cited paper, moreover, several smaller facets on maxillary as well as mandibular teeth are described; as here the situation of the maxillary dentition in respect to the mandibular toothrow was known it could be definitely proven that the facets are the result of contact of antagonistic teeth (loc. cit., pp. 237 — 239, figs. 14 and 16).

All the hitherto described facets of mandibular teeth of the Sperm Whale were of comparatively small length, so that they were confined to the crown of the teeth only (in this case the crown may be defined as the part of the tooth projecting above the gum). In the two specimens described below, however, the facets run from the top of the tooth to about half way its length, so that here during the contact of the antagonistic teeth the tops of the maxillary teeth must at least have come into contact with the gum of the lower jaw, and probably penetrated into the gum.

Judging by their size and shape the two teeth are from the lower jaws of female Sperm Whales, but as they as yet do not show any signs of a beginning basal occlusion of the pulp cavity it is not out of the question that they might have been taken from the jaws of young males. One (fig. 2) is from a left mandibula, the other (fig. 3) from a right mandibula. The two teeth are of a similar shape, both are slightly curved and have a rather sharp top.

One of these teeth (fig. 2) has a length of 137 mm and a greater transverse diameter of 41 mm; it has a smoothly conical pulp cavity with a height of 76 mm. At the lingual surface from the top to about half way the length of the tooth there are a number of facets running in a longitudinal direction; each of these facets has a breadth of up to 5 mm. This indicates that the tooth during the act of feeding was rubbing against a tooth in the upper jaw, whilst the mutual position of the two antagonistic teeth during this process did not remain absolutely fixed. From time to time the position of at least one of the teeth (probably the maxillary tooth which must have been less strongly fixed in the gum than the mandibular tooth) slightly shifted its position so that the manner of contact of the two teeth took place in a slightly different way. The facets are continued to about half way the length of the tooth, a region that undoubtedly was below the surface of the gum. Apparently here the

parodontal tissue was partially destroyed which gave rise to a pathological development of this part of the tooth. Possibly also foreign matter became imbedded in the opening between the tooth and the gum, which may have had its influence on the process of inflammation starting here. Absorption of a small part of the tooth tissue has taken place, and as a reaction against this process some regeneration has occurred, so that at the lower margin of the region of absorption there is a small exostosis of tooth material extending downwards from this region. The root of the tooth is entirely normal except in the middle of the lingual surface where there is a longitudinal narrow opening extending from the area of absorption to the base of the root. The margins of this slit have slightly grown inwards. With the exception of this narrow open space the pulp cavity does not show any irregularities; as yet the process causing absorption of tooth tissue had not penetrated into the interior of the pulp cavity.

The other tooth (fig. 3) has a length of 135 mm and a greater transverse diameter of 35 mm. From the top to about half way the length of the tooth there is, in the middle of the lingual surface, a facet of a breadth of about 10 mm. As a matter of fact this facet ended downwards below the surface of the gum, so that here also the action of the maxillary tooth must have destroyed part of the parodontal membrane and of the adjacent gum, bringing about a distinct herd of inflammation. Here again introduction of foreign matter may have hastened the process of the pathological conditions. Just below the lower end of the facet there is a rather wide cavity which has a basal transverse diameter of 25 mm and extends upwards into the central part of the tooth for a distance of 35 mm. The conical pulp cavity has a depth of 55 mm, it shows a large cleft in the middle of the lingual surface of the tooth. Here again the margins of this opening are distinctly curved inwards. At each side of the large opening, just below the region of absorption of the tooth tissue, some regeneration of tooth tissue has occurred, so that two scaly exostoses are to be seen here.

COLYER's explanation for the causes of absorption of tooth tissue in the Sperm Whale cited above cannot be upheld for the specimen described and figured by him. This explanation, however, exactly holds for the two teeth of figs. 2 and 3 in the present paper, in so far that not pressure of adjacent teeth is the factor causing the abnormality, but prolonged contact of antagonistic teeth. The maxillary teeth causing the deformities of the mandibular teeth of figs. 2 and 3 must have been of fairly large size in contradistinction to the rudimentary condition of the teeth generally occurring in the upper jaw of the Sperm Whale.

LITERATURE

BOSCHMA, H., On the Teeth and some other Particulars of the Sperm Whale (Physeter macrocephalus L.). Temminckia, 3, (1938).

H. BOSCHMA: *Absorption of tooth tissue in the Sperm Whale.*

1

2

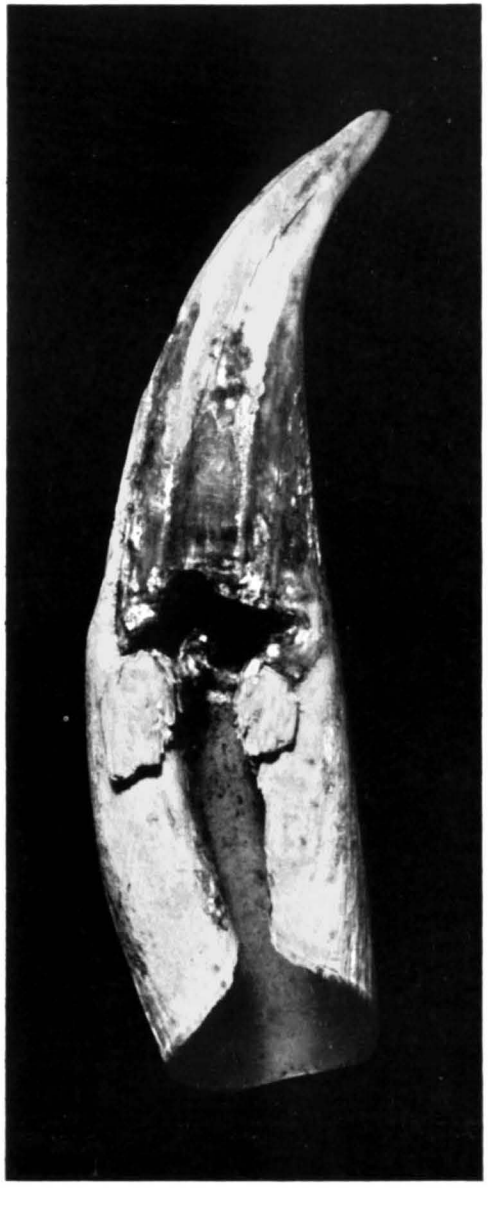

3

COLYER, J. F., Variations and Diseases of the Teeth of Animals. London, (1936).
NEUVILLE, H., Recherches comparatives sur la dentition des Cétodontes. Etude de morphologie et d'éthologie. Ann. Sc. Nat., Zool. (10), **15**, (1932).
POUCHET, G. and H. BEAUREGARD, Recherches sur le cachalot. Nouv. Arch. Mus. Hist. Nat. (3), **1**, (1889).

Fig. 1. *Physeter macrocephalus* L. Right (?) mandibular tooth of male specimen, probably lingual surface.

Fig. 2. *Physeter macrocephalus* L. Left mandibular tooth of female (?) specimen, lingual surface.

Fig. 3. *Physeter macrocephalus* L. Right mandibular tooth of female (?) specimen, lingual surface.

All figures approximately natural size.